

# The superior predictive value of $^{166}\text{Ho}$ -scout compared with $^{99\text{m}}\text{Tc}$ -macroaggregated albumin prior to $^{166}\text{Ho}$ -microspheres radioembolization in patients with liver metastases

Maarten L. J. Smits et al. *Eur. J. Nucl. Med. Mol. Imaging* 2019

## Background

Treatment planning for radioembolization of liver tumors is generally performed with technetium-99m-macroaggregated albumin ( $^{99\text{m}}\text{Tc}$ -MAA) however, as an alternative, a scout dose of  $^{166}\text{Ho}$ -Holmium-microspheres ( $^{166}\text{Ho}$ ) can be used prior to  $^{166}\text{Ho}$ -radioembolization, which may improve the predictive value pre-treatment analysis of distribution

## Objective

The aim of this study was to analyze whether the intrahepatic distribution of  $^{166}\text{Ho}$ -scout has a better agreement with the  $^{166}\text{Ho}$ -therapeutic dose distribution when compared with  $^{99\text{m}}\text{Tc}$ -MAA

## Methods

All patients treated in phase 1 and phase 2 Holmium Embolization Particles for Arterial Radiotherapy (HEPAR) studies were analyzed. These patients had unresectable liver metastases from various primaries (Fig. 1)

Two separate scout dose procedures include were performed ( $^{99\text{m}}\text{Tc}$ -MAA and  $^{166}\text{Ho}$ -scout) before treatment with  $^{166}\text{Ho}$ -radioembolization in 53 patients, a total of 55 procedures

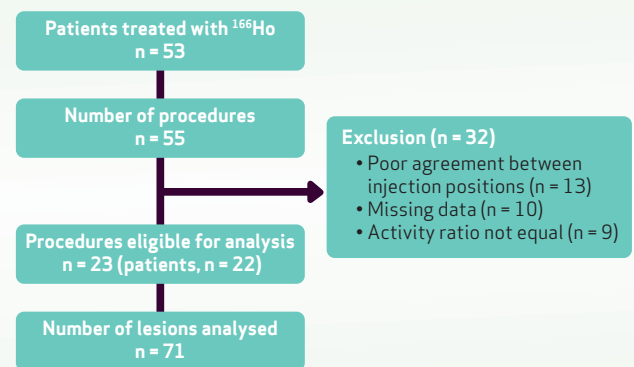


Fig 1: Inclusion flowchart of patient data

- 150 MBq  $^{99\text{m}}\text{Tc}$ -MAA (0.8mg, approximately 1.8 million particles TechneScan LyoMAA: Mallinckrodt Medical B.V., Petten, the Netherlands) was administered. Followed by planar- and SPECT/CT imaging to check for extrahepatic deposition and excessive lung shunting ( $>30\text{Gy}$ ). If no contraindications presented, the patient was scheduled for treatment 7 days later
- A **scout dose of  $^{166}\text{Ho}$ -microspheres** (consisting of approximately 3 million microspheres with an activity of 250MBq) was administered on the morning of the same day of treatment followed by planar- and SPECT/CT imaging
- Total **treatment activity** with  $^{166}\text{Ho}$  was planned based on aimed whole liver absorbed dose of 20, 40, 60 and 80Gy for HEPAR 1 patients, and 60Gy for HEPAR 2 patients
- All injections were performed with a standard 2.4F or 2.7F microcatheter (Progreat®, Terumo, Japan)

**Exclusion of cases** where differences in injection positions might have influenced distribution, was determined independently by 3 observers, using a 4-point scale. As a result, a total of 23 procedures (71 lesions, 22 patients) were included for analysis

Two blinded nuclear medicine physicians performed the **qualitative assessment** by visually rating the agreement between the  $^{99m}\text{Tc}$ -MAA,  $^{166}\text{Ho}$ -scout, and  $^{166}\text{Ho}$ -therapeutic dose SPECT-scans (i.e. all performed in the same patient) on a 5-point scale

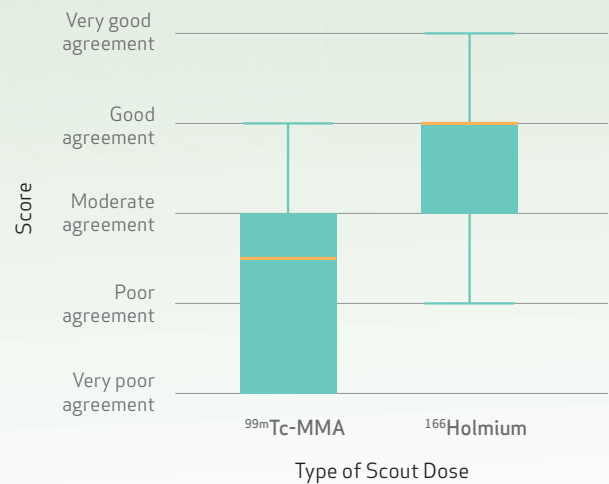
**Agreement of the intrahepatic distribution was measured quantitatively** by delineating lesions and normal liver on FDG-PET/CT. These volumes of interest (VOIs) were co-registered to the SPECT/CT images. The predicted absorbed doses (based on  $^{99m}\text{Tc}$ -MAA and  $^{166}\text{Ho}$ -scout) were compared with the actual absorbed dose on post-treatment SPECT

## Results

**Qualitative analysis:** In 15 procedures shown  $^{166}\text{Ho}$ -scout was superior, in 5 procedures MAA was superior and in 3 procedures there was no difference. As a result  $^{166}\text{Ho}$ -scout was superior with a median score of 4 vs 2.5 for  $^{99m}\text{Tc}$ -MAA ( $p < 0.001$ ) (Fig. 2)

**Quantitative analysis:**  $^{166}\text{Ho}$ -scout performed significantly better with significantly narrower 95%-limits of agreement compared with  $^{99m}\text{Tc}$ -MAA when evaluating lesion absorbed dose (-90.3 and 105.3 Gy vs -164.1 and 197.0 Gy respectively)

Evaluation of normal liver absorbed dose did not show a statistically significant difference in agreement between both scout doses and  $^{166}\text{Ho}$ -therapeutic dose



**Fig. 2:** Box plot. Scores of the overall agreement between both  $^{99m}\text{Tc}$ -MAA and  $^{166}\text{Ho}$ -scout and  $^{166}\text{Ho}$ -therapeutic dose of all 23 procedures are plotted in a box plot. Median and interquartile lines are indicated. Holmium scout dose performs significantly better than  $^{99m}\text{Tc}$ -MAA ( $p < 0.001$ )

## CONCLUSION

$^{166}\text{Ho}$ -scout has shown to have a superior predictive value for intrahepatic distribution in comparison to  $^{99m}\text{Tc}$ -MAA prior treatment with  $^{166}\text{Ho}$ -radioembolization

### Key Takeaway

- Use of  $^{166}\text{Ho}$ -scout dose can improve treatment planning for  $^{166}\text{Ho}$ -radioembolization in comparison to  $^{99m}\text{Tc}$ -MAA prior treatment with  $^{166}\text{Ho}$ -radioembolization